

Prevention of tri-nitrobenzene of sulfonic acid-induced colitis in chicken by using extract of *Aloe vera*

Motamed Elsayed Mahmoud, Khaled M. A. Hassanein¹

Department of Animal Husbandry, Faculty of Veterinary Medicine, Sohag University, Sohag, Egypt.
1. Department of Pathology and Clinical Pathology, Faculty of Veterinary Medicine, Assiut University, Assiut 71526, Egypt.

Corresponding author: Khaled M. A. Hassanein, E-mail: kh-hassanien@hotmail.com

Received: 04-01-2012, Accepted: 23-01-2012, Published Online: 31-05-2012

doi: 10.5455/vetworld.2012.469-476

Abstract

Aim: *Aloe vera*, species of succulent plant in the genus *Aloe*, has multiple clinical activities and used routinely to accelerate wound healing. The present study was designed to investigate the anti-inflammatory effect of *Aloe vera* extracts (AVE) in vitro and in vivo.

Materials and Methods: The effect of crude AVE on inducible nitric oxide production by LPS/IFN γ -stimulated cultured macrophages was evaluated. The therapeutic effect of administering crude *Aloe vera* extracts (100 mg/kg b.w.) on the development of tri-nitrobenzene of sulfonic acid (TNBS)-induced colitis (40 mg/kg b. w.) in chicken was also investigated. Chicken is a valuable model for this purpose because it showed preference to bitter taste of *Aloe vera*. Diverse clinical pictures of the colitis including weight loss, diarrhea and histopathological changes were evaluated.

Results: Nitrite production by LPS/IFN γ -stimulated macrophages was maximally reduced by adding of AVE (100 μ g/ml). This result suggests a direct inhibitory effect of AVE on the inflammatory cells. Chicks treated orally with AVE showed improvement of the histological signs with no inflammatory cell infiltrates and reduction of myeloperoxidase (MPO) activities when compared with colitis control group. AVE pretreatment ameliorated significantly the clinical and histopathological severity of the TNBS-induced colitis; decreased body weight loss and diarrhea and increased survival.

Conclusion: It was concluded that oral administration of AVE represents a valuable therapeutic approach for the treatment of colitis in chicken.

Keywords: *Aloe vera*, Colitis, TNBS, Chicken, Macrophages, Enzyme Assay.

To cite this article:

Mahmoud ME, Hassanein KMA (2012) Prevention of tri-nitrobenzene of sulfonic acid- induced colitis in chicken by using extract of *Aloe vera*, *Vet World* 5(8): 469-476. doi: 10.5455/vetworld.2012.469-476

Introduction

Several experimental models of colitis have been developed in animals. The hapten-induced model of colonic inflammation in which 2, 4, 6-trinitrobenzene sulfonic acid (TNBS) is delivered intrarectally displays the pathologic and clinical picture to human colitis and it is used as a model system to test potential therapeutic agents [1]. Despite the colitis in chicken is a frequent problem associated with many infections such as coccidiosis and colostridiosis [2], induction of experimental colitis by TNBS in chicken is not well investigated. In TNBS-induced colitis, intestinal inflammation results from a binding of the haptenizing agent to autologous host proteins with subsequent stimulation of lymphocytes and exaggerating macrophage and leucocytic infiltration and activation giving rise to a prolonged severe transmural inflamed intestinal mucosa [1].

Aloe species is widely used in the food medicines and pharmaceutical industries due to its anti-inflammatory activity [3], antioxidant activity [4], acceleration of wound and gastric ulcer healing [3,5], protection against hepatic and cardiac injuries [6,7], parasitic infestation and bacterial and viral infections [8-10]. It was reported that the single most commonly used type of complementary and alternative medicine for gastrointestinal disorders is herbal therapy [11]. *Aloe vera* has an anti-inflammatory action by inhibiting the production of proinflammatory cytokines by activated monocytes and endothelial cells [12]. *Aloe* anthraquinones and chromone have strong anti-inflammatory effects in murine macrophages [2]. Based on this wide anti-inflammatory action, we investigated the potential therapeutic effect of AVE in the chicken model of TNBS-induced colitis.

In this study, we investigated the anti-

inflammatory effect of *Aloe vera* extracts (AVE) in vitro and in vivo. The effect of crude AVE on inducible nitric oxide production by LPS/IFN γ -stimulated cultured macrophages was evaluated. The effects of crude AVE on inflammatory responses of TNBS-induced chicken colitis were also investigated.

Materials and methods

Reagents: RPMI 1640 supplemented with glutamine was purchased from ICN Biomedicals (Aurora, OH, USA) and all remaining reagents were obtained from Sigma (Louis, MO, USA).

Preparation of AVE: *Aloe vera* extract (AVE) leaves were identified in Department of Botany, Faculty of Science, Assiut University, Egypt. Water soluble AVE was extracted according to previously described method [13] with slight modifications. In brief, juice was collected from fresh plants via small incisions along the leaves. Then, the collected juice was centrifuged at 1800 rpm for 10 min to remove solid particles, extracted with boiled water and freeze dried. Ten grams of AVE powder was dissolved in 100 ml of phosphate-buffered saline (PBS) just before use in each experiment.

Animals and Housing Conditions: A total of 96 one-day-old-specific pathogen-free (SPF) chickens (Hubbard strain, Elwady Co. Egypt) within body weight range of 40-50g and reared at Veterinary Teaching Hospital in Faculty of Vet. Med., Assiut University, Assiut, Egypt. The chickens were distributed randomly and kept under controlled conditions in isolation units (size: 1.2 m²) with the airflow of 35 to 40 m³/h. The temperature was adjusted at 35 °C during the first week of life and later on reduced gradually (0.5°C per day) to 25°C by the age of 3 wks. Light period was kept at 12 hr throughout the trial. Feed and water were provided ad libitum. Ethics and experimental procedures were approved by Assiut University Animal Care and Use Committee.

In vitro study:

Preparation of primary cell culture: Abdominal exudate cells were collected and purified as previously described [14]. Briefly, a Sephadex (Sephadex G-50 super fine, Sigma) suspension was prepared in distilled water and finally resuspended in saline (0.85%) at a concentration of 3%. Chicks (5 days of age, 60–80 g in body mass) were injected intraperitoneally with Sephadex solution at 1 mL/50 g body mass in the left anterior abdominal quadrant. After 3 days, chicks were decapitated and abdominally area was defeathered and de-skinned and flushed with 70%

ethanol. Approximately 12 mL of peritoneal wash was recovered per chick. The cells were harvested by centrifugation at 1000 rpm for 10 min. Then pooled cells from 10 to 15 chicks were resuspended in RPMI 1640 containing 10% heat-inactivated fetal calf serum, 1% chicken serum, 200 µg/mL gentamycin and 100 U/mL penicillin. Cell counts and viability assessment were made using Trypan blue exclusion stain.

The cells were suspended in the RPMI 1640 complete medium and seeded in culture flasks to obtain purified macrophages. After 2 h of incubation at 41 °C and 5% CO₂, non-adherent cells were washed away and adherent cells were re-incubated with fresh medium. Cells harvested by scraping were resuspended in serum-free medium and inoculated at 1.0×10⁶ cells/mL. Cultured macrophage cells were incubated with AVE (1, 10 and 100 µg/ml) in the presence or absence of LPS (1 µg/mL) + IFN γ (100U) at 41 °C. After 24 h of incubation, culture supernatants were collected for nitrite assay.

Measurement of nitrite: The level of nitrite, a stable product of NO was measured by Griess reaction as described by [15]. Samples (100 µL/well) were incubated with an equal volume of Griess solution (Sigma) in darkness at room temperature for 10 min. Optical densities at a wavelength of 540 nm were evaluated by an ELISA reader (Stat Fax, 2100, Awareness Tech. USA). A standard curve was made by various concentrations of sodium nitrite to calculate concentrations of nitrite in the culture supernatant.

In vivo study:

Drinking bottles preference test : Two drinking bottles preference test was performed according to [16]. Chicks were allowed to drink from 2 bottles; AVE (1% in tap water) and PBS in water during the 1st two weeks of age. Other control groups were exposed to water only. Counter balanced drinking bottles of the same size and color were used. The bottles were orientated from time to time per day to preclude the location preference. Water intake was recorded and the average daily measures were computed daily. Obtained values for water intake rate were standardized (ml /g. b.w.) to avoid the effect of differences in body weight per se on the amount of water consumed by each chick. Three independent experiments were performed for chicks (n = 20).

Experimental design, induction and assessment of colitis: Colitis was induced in chick (3 weeks old) as previously described [17]. Chicks were gently handled, and a 3.5F catheter was inserted

Table-1. Summarized the experimental design.

Group	Days of experiment								
	1st	2nd	3rd	4th	5th	6th	7th	8th	9th
G1 Vehicle only	Vehicle	Vehicle	Vehicle	decapitation (n = 10)	-	Vehicle	-	decapitation (n = 10)	decapitation (n = 10)
G2 TNBS + vehicle	TNBS	Vehicle	Vehicle	decapitation (n = 10)	-	-	-	-	-
G3 AVE- before TNBS	AVE	AVE	AVE	TNBS	-	-	-	decapitation (n = 10)	-
G4 AVE- after TNBS	TNBS	AVE	AVE	AVE	-	-	-	decapitation (n = 10)	-
G5 TNBS- AVE-TNBS	TNBS	AVE	-	-	-	TNBS	-	-	decapitation (n = 10)

intracloacally 5 cm from the vent. To induce colitis, 40 mg/kg b. w. of TNBS (Sigma Chemical Co, St. Louis, MO) was dissolved in a 1:1 mixture (1 ml) of NaCl 0.9% and ethanol (100%) and slowly administered into the colon via the catheter filled to a 3-mL syringe. Control chicks received 50% ethanol alone. Chicks were daily administered for 3 consecutive days with PBS or AVE (100 mg/kg b.w.) 24 hours before TNBS instillation. To study the therapeutic effect of delayed administration of AVE on established colitis, AVE (100 mg/kg b.w.) was daily administered for 3 consecutive days starting 6 days after TNBS administration. Chicks were monitored daily for appearance of diarrhea, body weight loss, and survival. Some chicks were killed at the peak of the disease (day 4), blood samples were collected by cardiac puncture and a segment of the colon (5 cm long) was excised for macroscopic damage evaluation and weighed. Tissue segments were immediately subjected for histopathological studies. In another set of experiments, colon segments were immediately used for enzyme assay (Table 1).

Clinical picture: Development of colitis and severity of inflammation have been scored using a clinical disease activity index ranging from 0 to 4 that will be calculated as previously described [18] using the following parameters: droppings consistency (scored as: 0, well formed droppings; 2, loose droppings; 4, diarrhea), presence or absence of blood (0 = no blood, 2 = occult of blood, 4 = gross bleeding) and weight loss.

Gross pathology and histopathology: The chicks subjected to gross pathological examination. Specimens from colon were fixed in 10% neutral buffer formalin, dehydrated in a graded alcohol series, cleared with methyl benzoate and embedded in paraffin wax. Four micron sections were cut and stained with haematoxylin and eosin (HE) for histopathological examination by light microscopy [19].

Myeloperoxidase (MPO) assay: Chicks will be killed at previously indicated time points for enzymatic assay of colonic myeloperoxidase (MPO) activity, an index of granulocytic infiltration, was measured according to the standard method of [20]. Ten grams of wet colon segment was homogenized in 50 mM potassium phosphate buffer at pH 6.0 containing 0.5% hexadecyltrimethylammonium bromide. The homogenized samples were then frozen–thawed and sonicated three times and centrifuged at 4000 rpm for 15 min at 4 °C. The supernatant (100 µl) was mixed with 2.9 ml of 50 mM potassium phosphate buffer (pH 6.0) containing O-dianisidine hydrochloride and hydrogen peroxide. Changes in absorbance at 470 nm were measured with spectrophotometer (Cecil 292, Cambridge, England) over 5 min. The MPO activity was calculated from the rate of change absorbance during 1 min. The results were expressed as MPO units/g wet tissue; 1 unit of MPO activity was defined as degrading 1 µmol hydrogen peroxide/ min at 25 °C.

Statistical analysis: All values are expressed as mean ± SD. Data were evaluated statistically by one-way ANOVA (TNBS, addition of AVE). Survival curve was analyzed by the Kaplan–Meier log-rank test. Changes in body weight were compared by use of the Wilcoxon matched-pair signed-rank test. Differences between treatment means were tested according to Duncan's multiple range tests. All analyses were performed in SPSS software for window version 14 (SPSS Inc. USA). Probability values < 0.05 were considered statistically significant.

Results

AVE inhibits nitrite production in LPS-stimulated chicken peritoneal macrophages: We investigated the effects of crude AVE on inducible nitric oxide production by LPS/IFN γ -stimulated macrophages. Isolated chicken peritoneal macrophages were maximally stimulated with LPS (1 µg/mL) and INF γ (100U/ml) in the presence or absence of AVE. Non-

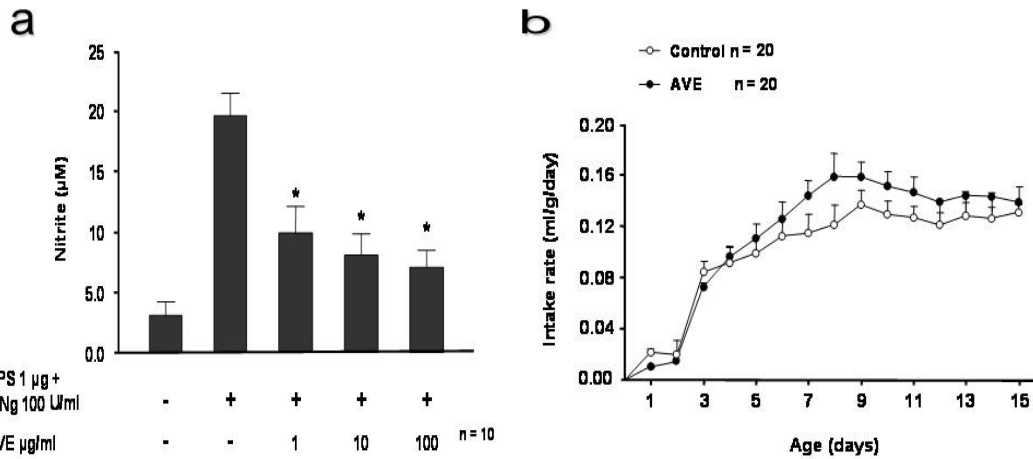


Figure-1. a) Effects of AVE on nitrite production by LPS/IFN gamma- stimulated peritoneal macrophages. Data are presented as mean \pm SD. The data shown are representative of three experiments. * $P < 0.01$ versus LPS/IFN gamma-treated cells. b) The preference of chicks to AVE or water was assessed starting from one day-15th day old by using bottles preference tests. Chicks were subjected to one bottle with drinking tap water and the other with AVE (10 mg/ml). Intake rate was standardized into grams b. w. Each point represents mean \pm SD. N = 20 chicks/group.

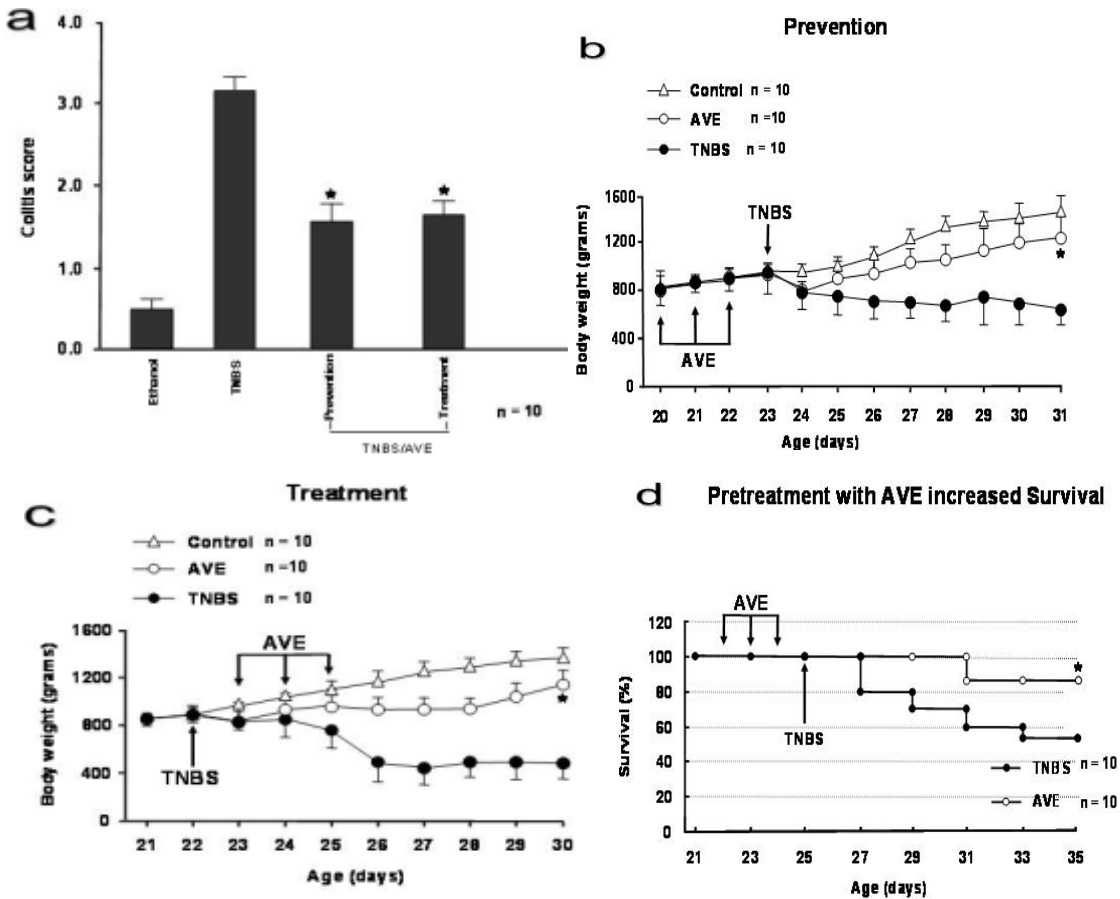


Figure-2. Treatment with AVE protects against TNBS-induced colitis. Clinical evolution and severity were monitored by colitis score (a), body weight changes (b, c), and survival (d). N = 10 chicks/group. * $P < 0.01$ versus TNBS-treated chick.

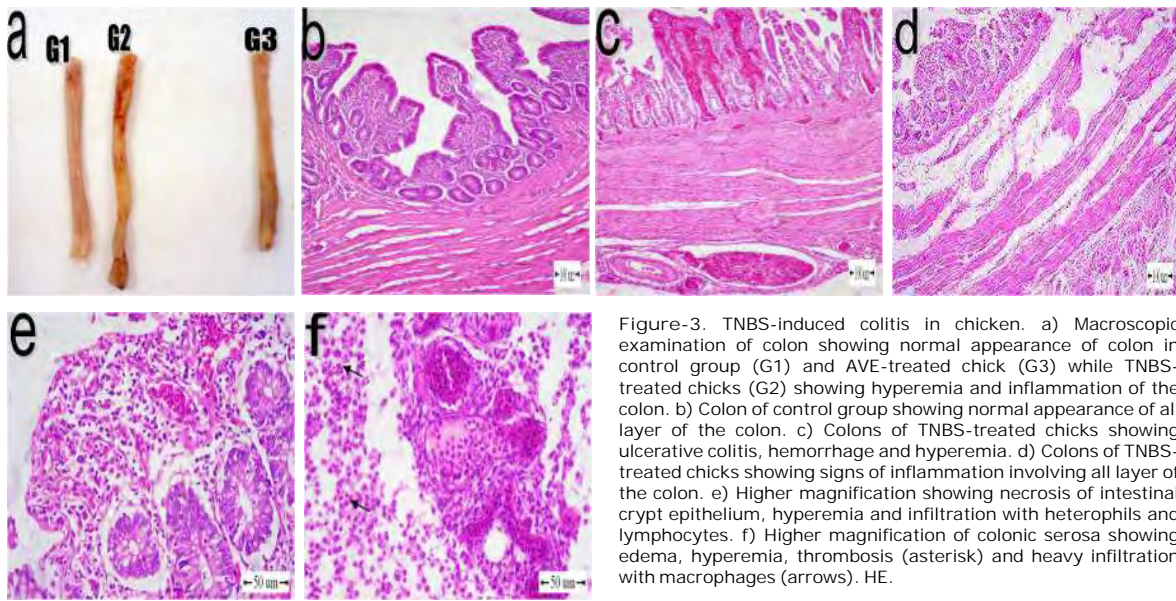


Figure-3. TNBS-induced colitis in chicken. a) Macroscopic examination of colon showing normal appearance of colon in control group (G1) and AVE-treated chick (G3) while TNBS-treated chicks (G2) showing hyperemia and inflammation of the colon. b) Colon of control group showing normal appearance of all layer of the colon. c) Colons of TNBS-treated chicks showing ulcerative colitis, hemorrhage and hyperemia. d) Colons of TNBS-treated chicks showing signs of inflammation involving all layer of the colon. e) Higher magnification showing necrosis of intestinal crypt epithelium, hyperemia and infiltration with heterophils and lymphocytes. f) Higher magnification of colonic serosa showing edema, hyperemia, thrombosis (asterisk) and heavy infiltration with macrophages (arrows). HE.

treated macrophages, without LPS/IFN γ stimulation, produced minimal levels of nitrite ($3.1 \pm 1.4 \mu\text{M}$). However, 24 h after stimulation, nitrite production was markedly increased ($19.1 \pm 3.5 \mu\text{M}$). Nitrite production was maximally reduced by adding of AVE ($100 \mu\text{g/ml}$) to $7.3 \pm 1.3 \mu\text{M}$ as shown in (Fig. 1a). This result suggests a direct inhibitory effect of AVE on the inflammatory cells.

Drinking bottles preference test: The drinking bottles preference test started from one day-old post-hatching. The preference values for 3 independent experiments were restricted between AVE and water only (Fig. 1b). There were no any noticeable differences between the control preferences to either drinking water or AVE (10 mg/ml).

Treatment with AVE protects against colitis development: Chicks subjected to intracolonic administration of TNBS in 50% ethanol developed a severe illness characterized by watery diarrhea, colitis accompanied by reduced body weight, and a profound and sustained weight loss resulting in a mortality of about 43% (Fig. 2). AVE administration resulted in a 62.5% reduction in the clinical disease activity index (Fig. 2a). Chicks pretreated once daily for 3 days with AVE (100 mg/kg b. w.) before TNBS instillation had a survival rate of 87%, rapidly recovered the lost body weight and regained a healthy appearance similar to control chicks treated with 50% ethanol alone (Figs. 2b-d).

Macroscopic examination of colons obtained 4 days after colitis induction showed inflammation in

the form of striking hyperemia and necrosis in TNBS-injected chicks compared with control chicks and AVE-after TNBS injection showed no signs of macroscopic inflammation (Fig. 3a). Histopathological examination of the colon of chicks in control group showed normal histological appearance (Fig. 3b). Chicks given TNBS-injected chicks showed transmurular inflammation involving all layers of the colon with marked increase in the thickness of the muscular layer and serosa. The epithelium of the intestinal crypts showed necrosis, ulceration and pronounced depletion of goblet cells. Hyperemia, hemorrhage, edema and thrombosis of some blood vessels especially in the serosa were also seen. Inflammatory cell infiltrates consisted of macrophages, lymphocytes and heterophils in all layers of the colon (Figs. 3c-f). When chicks treated with AVE, improvement of the histological signs with no inflammatory cell infiltrates and appeared as control group (Fig. 4a). The AVE-before TNBS injection group showed normal appearance of the colon except one case revealed desquamation of the epithelial lining and some leucocytes infiltrate (Figs. 4b,c). The corresponding colitis score were shown in (Fig. 2a).

Treatment with AVE reduces systemic and colonic inflammatory responses in chicken with TNBS-induced colitis: The effect of AVE (100 mg/kg b.wt.) after injection of TNBS on the production of inflammatory mediators was evaluated. AVE administration resulted in about 62.5% reduction in the clinical disease activity index (Fig. 2a).

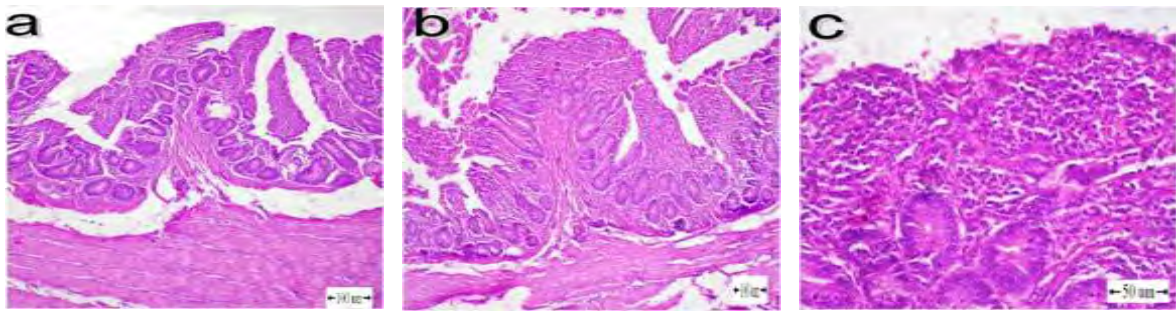


Figure-4. Effect of AVE on TNBS-induced colitis in chicken. a) Colon of AVE-treated group showing normal appearance of all layers. b, c) Colon of AVE-prevented group showing desquamation of the epithelium and mononuclear infiltration. HE.

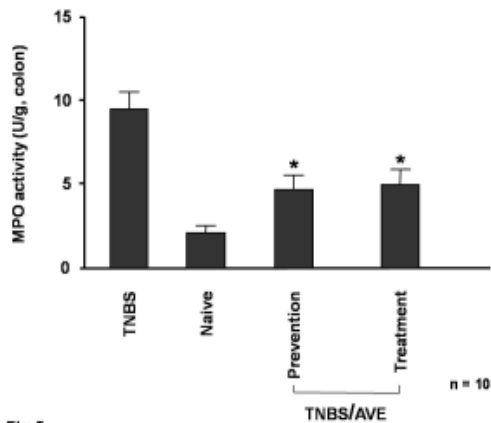


Figure-5. Effect of AVE on colonic MPO activity. AVE decreases colonic inflammatory responses in the TNBS model of chicken colitis. N = 10 chicks/group. *P < 0.001 versus TNBS-treated chicks.

Fig.5

Administration of AVE after TNBS injection resulted in significant amelioration of colitis by day 8 after TNBS instillation, as shown by improvement in body weight and dropping consistency. No such effect was observed when the delayed effect of AVE on established colitis group was investigated (data not shown).

Treatment with AVE reduces MPO activity: Administration of AVE after TNBS reduced MPO activities to about 5.6 and 4.8 units/g colon respectively (Fig. 5).

Discussion

In TNBS-induced colitis, intestinal inflammation results from binding of the hapten to autologous host proteins with subsequent stimulation of T-lymphocytes and exaggeration of macrophage and neutrophil infiltration and activation, giving rise to a prolonged severe transmural inflamed intestinal mucosa. TNBS-induced colitis is characterized by uncontrolled production of inflammatory cytokines and chemokine [1]. In the present study, AVE acts as a macrophage-deactivating factor by down-regulating

the production of a nitric oxide when maximally stimulated by combination of LPS and IFN-gamma. The key molecules on which ABE acts remain to be elucidated.

This inflammatory model has been induced in chicken by using TNBS. Chicken was found to be indifferent to pain burning sensation of hot chilli peppers [21]. We found that chicken is also indifferent to bitter taste of AVE. Therefore these experiments were designed to investigate the effect of oral administration of AVE on TNBS-induced colitis in chicken. The anti-inflammatory effects of AVE are associated with reductions of (i) the recruitment of inflammatory cells; (ii) ultimate tissue injury; (iii) body weight loss; (iv) enzymatic activity and (v) production of nitric oxide in activated macrophage in vitro. AVE was an especially potent inhibitor to TNBS-induced colitis, suggesting that it would be useful in controlling inflammatory disorders.

Products derived from AVE plant have multiple clinical activities, and they are used routinely to accelerate wound healing [22] and they have anti-inflammatory [23] and antioxidant property [24]. *Aloe*

vera had received considerable attention for its use in drug formulation [2]. In the present study, AVE strongly reduced mucosal inflammation by down-regulating the production of mediators involved in the local and systemic inflammatory response. MPO is an enzyme found in neutrophils. Its activity in the colon is considered to be a marker of tissue inflammation and it is related linearly to neutrophil infiltration [25].

In this study, colonic MPO activity was significantly increased in the TNBS control chicks compared to that of the non-colitic chicks, indicating that heterophils (analogue to mammalian neutrophil) play important roles in TNBS-induced colitis. Hence, the inhibition of MPO activity by AVE contributes in part to their anti-inflammatory effect. In particular, MPO activity in the AVE-treated groups was lower than that of the other groups which effectively inhibits colitis progression. Results from this study showed that AVE effectively suppressed both histological and biological changes in TNBS-induced colitis of chicken.

Aloesin (a product of *Aloe vera*) is a strong inhibitor of plasma LTB₄ level which helps in the activation and recruitment of inflammatory cells and consequent perpetuation of inflammatory bowel diseases [26,27]. These aloe products reduce the accumulation of neutrophils and leukocytes within the mucosa of mammals and have antioxidant properties [28]. This could partially explain the reduction of inflammatory infiltrates in the colonic mucosa of chicken treated with AVE. As well to the regulation of cell recruitment to the lamina propria during colitis, AVE regulates inflammatory cell activation and cytokine production. Hence, it is recently reported that AVE has an anti-inflammatory action by inhibiting the production of proinflammatory cytokines such as IL-6 and TNF alpha by activated monocytes and endothelial cells [12,29,30]. A recent study performed with human cells demonstrated that monocytes are the main targets for the anti-inflammatory action of *Aloe sp.* Since, it has been also reported that aloe anthraquinones and chromone have strong anti-inflammatory effects in murine macrophages [2].

Conclusion

In conclusion, our results demonstrate oral administration of AVE, a bitter substance preferable to chicken, ameliorates the intestinal inflammation response of TNBS-induced colitis in chicken. AVE is a potent inhibitor to cell infiltration and recruitment to the colon, and that these inhibitory effects are caused by inhibition of enzymes MPO activities. In vitro

study indicated that AVE reduced nitric oxide production in treated peritoneal macrophages cells with LPS/IFN gamma. The results might suggest potential uses of AVE as an effective anti-colitic agent.

Author's contribution

MEM and KMAH participated in the preparation of experimental design and the facilities of the research. MEM setting up the invitro study, measurement of nitrite and MPO, analysed the data. KMAH done the gross and histopathological study. Both author prepared the manuscript. Both author read and approved the final manuscript.

Acknowledgements

This study was supported by a scientific research fund of the Egyptian Ministry of Higher Education and Scientific Research.

Competing interest

Authors declare that they have no conflict of interest.

References

1. Strober W., Fuss I.J., Blumberg R.S. (2002). The immunology of mucosal models of inflammation. *Annu. Rev. Immunol.*, 20: 495–549.
2. Park S.S., Lillehoj H.S., Allen P.C., Park D.W., Fitz-Coy S., Bautista D.A., Lillehoje E.P. (2008). Immunopathology and cytokine responses in broiler chickens coinfecting with *Eimeria maxima* and *Clostridium perfringens* with the use of an animal model of necrotic enteritis. *Avian Dis.*, 52:14–22.
3. Park C.H., Nam D.Y., Son H.U., Lee S.R., Lee H.J., Heo J.C., Cha T.Y., Baek J.H., Lee S.H. (2011). Polymer fraction of *Aloe vera* exhibits a protective activity on ethanol-induced gastric lesions. *Int. J. Mol. Med.*, 27:511–518.
4. Kammoun M., Miladi S., Ali Y.B., Damak M., Gargouri Y., Bezzine S. (2011). In vitro study of the PLA2 inhibition and antioxidant activities of *Aloe vera* leaf skin extracts. *Lipids Health Dis.*, 11:10–30.
5. Dart A.J., Dowling B.A., Smith C.L. (2005). Topical treatments in equine wound management. *Vet. Clin. North Am. Equine Pract.*, 21:77–89.
6. Kim S.H., Cheon H.J., Yun N., Oh S.T., Shin E., Shim K.S., Lee S.M. (2009). Protective effect of a mixture of *Aloe vera* and *Silybum marianum* against carbon tetrachloride-induced acute hepatotoxicity and liver fibrosis. *J. Pharmacol. Sci.*, 109:119–127.
7. Yagi A., Takeo S., (2003). Anti-inflammatory constituents, aloesin and aloemannan in *Aloe* species and effects of tanshinon VI in *Salvia miltiorrhiza* on heart. *Yakugaku. Zasshi.*, 123: 517–532.
8. Waihenya R.K., Mtambo M.N., Nkwengulila G. (2002a). Valuation of the efficacy of the crude extract

- of *Aloe secundiflora* in chickens experimentally infected with Newcastle disease virus. *J. Ethnopharmacol.*, 79:299–304.
9. Waihenya R.K., Mtambo M.N., Nkwengulila G., Minga U.M., (2002b). Efficacy of crude extract of *Aloe secundiflora* against *Salmonella gallinarum* in experimentally infected free-range chickens in Tanzania. *J. Ethnopharmacol.*, 79:317–23.
 10. Yim D., Kang S.S., Kim D.W., Kim S.H., Lillehoj H.S., Min W. (2011). Protective effects of *Aloe vera*-based diets in *Eimeria maxima*-infected broiler chickens. *Exp. Parasitol.*, 127:322–325.
 11. Kaplan M., Mutlu E.A., Benson M., Fields J.Z., Banan A., Keshavarzian A. (2007). Use of herbal preparations in the treatment of oxidant-mediated inflammatory disorders. *Complement Ther. Med.*, 15 :207-16.
 12. Habeeb F., Stables G., Bradbury F., Nong S., Ameron P., Plevin R., Ferro V.A. (2007). The inner gel component of *Aloe vera* suppresses bacterial-induced pro-inflammatory cytokines from human immune cells. *Methods*, 42:388–93.
 13. Mahmoud M.E., Hesham A., Ahmed Y.A., Sayed M. (2010). Inhibition of melanogenesis by the extract from *Agaricus blazei* without affecting iNOS gene expression. *World J. Microbiol. Biotechnol.*, 26: 2029–2035.
 14. Mahmoud M.E., Shimizu Y., Shiina T., Nikami H., Dosoky R.M., Ahmed M.M., Takewaki T. (2007). Involvement of a capsaicin-sensitive TRPV1-independent mechanism in lipopolysaccharide-induced fever in chickens. *CBB, Part A* 148: 578–583.
 15. Green L.C., Ruiz D.L., Wagner D.A. (1981). Nitrate biosynthesis in man. *Proc. Nat. Acad. Sci.*, 78:7764–7768.
 16. Duncan I.J. (1992). Measuring preferences and strength of preferences. *Poultry Sci.*, 71: 658–663.
 17. Gurung Y.B., Shimizu Y., Shiina T., Mahmoud M.E., Saito S., Takewaki T. (2007). Impairment and restoration of spontaneous contractile activity of longitudinal smooth muscles in the TNBS-inflamed hamster distal colon. *Biomedical Research*, 28:301–308.
 18. Fiorucci S., Mencarelli A., Palazzetti B., Distrutti E., Vergnolle N., Hollenberg M.D., Wallace J.L., Morelli A., Cirino G. (2001). Proteinase-activated receptor (PAR)-2 is an anti-inflammatory signal for colonic lamina propria lymphocytes in a mouse model of colitis. *Proc. Nat. Acad. Sci.*, 98: 13936–13941.
 19. Bancroft T.D., Stevens A., Turner D.R. (1996). *Theory and practice of histological technique*, 4th edition. Churchill, Livingston, New York, London, San Francisco, Tokyo.
 20. Bradley P.P., Priebe D.A., Christensen R.D., Rothstein G. (1982). Cellular and extracellular myeloperoxidase in pyogenic inflammation. *J. Invest. Dermatol.*, 78:206–209.
 21. Jordt S.E., Julius D. (2002). Molecular basis for species specific sensitivity to “hot” chili peppers. *Cell*, 108:421–430.
 22. Talmadge J., Chavez J., Jacobs L., Munger C., Chinnah T., Chow J.T., Williamson D., Yates K. (2004). Fractionation of *Aloe vera* L. inner gel, purification and molecular profiling of activity. *Int. Immunopharmacol.*, 4(14):1757–73.
 23. Zhang L., Tizard I.R. (1996). Activation of a mouse macrophage cell line by acemannan: The major carbohydrate fraction from *Aloe vera* gel. *Immunopharmacology*, 35:119–128.
 24. Rajasekaran S., Sivagnanam k., Subramanian S. (2005). Antioxidant effect of *Aloe vera* gel extract in streptozotocin-induced diabetes in rats. *Pharmacological Report*, 57: 90–96.
 25. Krawisz J.E., Sharon P., Stenson W.F. (1984). Quantitative assay for acute intestinal inflammation based on myeloperoxidase activity. Assessment of inflammation in rat and hamster models. *Gastroenterology*, 87:1344-1350.
 26. Eberhart C.E., Dubois R.N. (1995). Eicosanoids and the gastrointestinal tract. *Gastroenterology*, 109:285-301.
 27. Langmead L., Rampton D.S. (2006). Review article: complementary and alternative therapies for inflammatory bowel disease. *Aliment. Pharmacol. Ther.*, 23:341-349.
 28. Zhang X.F., Wang H.M., Song Y.L., Nie L.H., Wang L.F., Liu B., Shen P.P., Liu Y. (2006). Isolation, structure elucidation, antioxidative and immunomodulatory properties of two novel dihydrocoumarins from *Aloe vera*. *Bioorg. Med. Chem. Lett.* 16:949-53.
 29. Esua M.F., Rauwald J.W. (2006). Novel bioactive maloyl glucans from *aloe vera* gel: isolation, structure elucidation and in vitro bioassays. *Carbohydrate Res.*, 27:355–364.
 30. Harhaji L., Mijatovic S., Maksimovic-Ivanic D., Popadic D., Isakovic A., Todorovic-Markovic B., Trajkovic V. (2007). *Aloe emodin* inhibits the cytotoxic action of tumor necrosis factor. *Eur. J. Pharmacol.*, 30:248–259.

* * * * *